



PRACTICAL APPROACHES FOR DIAGNOSIS AND TREATMENT OF POULTRY DISEASES

**A WORKSHOP HELD ON THE 6TH AUGUST 2014 IN
THE DEPARTMENT OF VPMP, FVM, COLLEGE OF
AGRICULTURE AND VETERINARY SCIENCES,
UNIVERSITY OF NAIROBI**



Misdiagnosis of Poultry Diseases at Necropsy

Presentation by

Dr Mahacla Odongo

Department of Veterinary Pathology, Microbiology and
Parasitology, Faculty of Veterinary Medicine,
University of Nairobi



Diagnosis and Misdiagnosis of Poultry Diseases at Necropsy



Diagnosis : Identification of the nature of illness or other problem by examination of the symptoms, PM lesions and laboratory investigation(s).

Misdiagnosis: Incorrect diagnosis

Correct diagnosis of Poultry disease based on:

1. Flock History
2. Clinical Signs/Symptoms
3. Postmortem lesions
4. Histopathology
5. Microbiological, Parasitological and Toxicological Laboratory investigations/Analysis using appropriate specimens
6. Serology and DNA methods (rarely)



Consequences of Misdiagnosis



- Loss of birds
- Waste of money and resources (wrong drugs used, Vet fees, etc)
- Spread of misdiagnosed infection
- Unwarranted Alarm to the poultry industry (reported as new infection)
- Misreporting
- Wrong control measures



Some of the most **Misdiagnosed** Poultry Diseases/Conditions at Necropsy



- Marek's disease
- Swollen Head Syndrome
- Newcastle disease
- Avitaminosis A
- Fusaritoxicoses
- Fowl Pox (Wet form)



Misdiagnosis of Poultry Disease



- Misdiagnosis of Poultry Disease is due to biased consideration of the above parameters
- Correct diagnosis of poultry disease: Parameters 1 to 5 must always be considered, and if facilities permit, parameter 6.
- In some cases, parameters 1 to 3 are adequate to confirm a diagnosis of a poultry disease, e.g the neural form of Marek's disease. In other cases one requires parameters 1 to 4, or 1 to 5 or all of them.



Marek's Disease

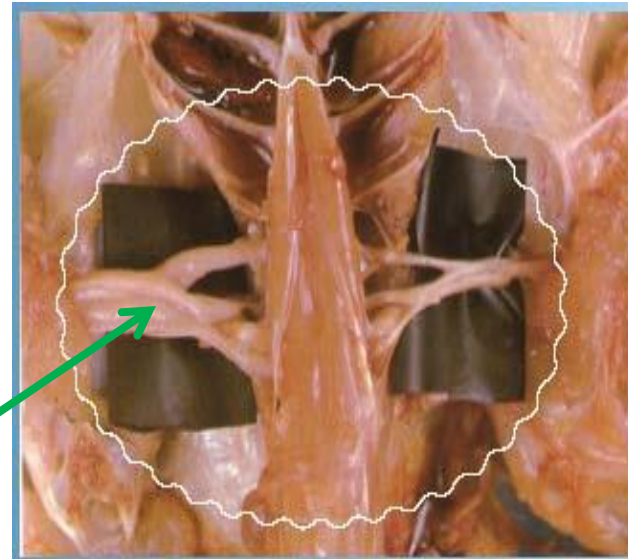


This disease occurs in two forms:

1. **Neural (Classical form)**- Classical Marek's disease is characterised by enlargement of peripheral nerves up to three times the normal size. Occasionally lymphomas (tumours) occur in visceral organs.
2. **Vicseral form**- Marek's disease occurs as tumours in internal organs, including the ovaries, liver, spleen, kidney and heart. Sometimes the skin is involved in which case we observe tumors of feather follicles



Neural form of MD



Enlarged sciatic nerve (pathognomonic)



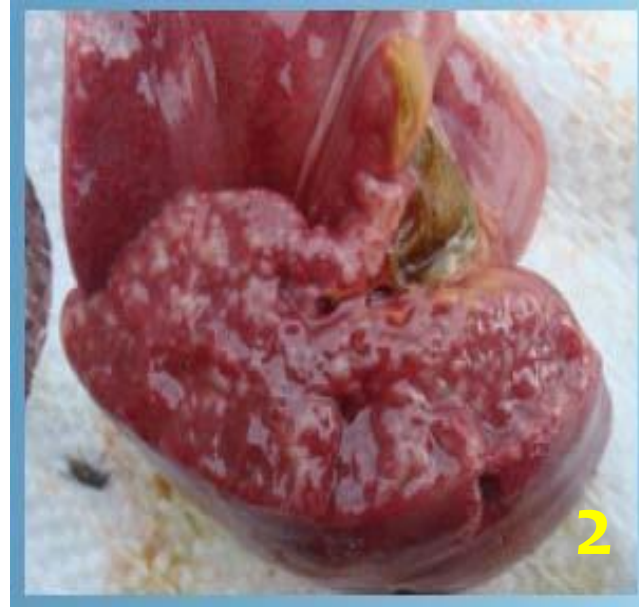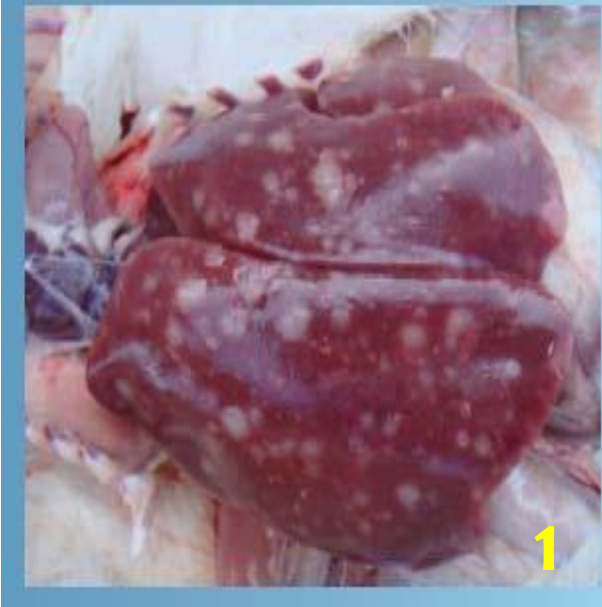Ocular form of MD



Opacity of the iris; may be irregularly shaped



Visceral form of MD





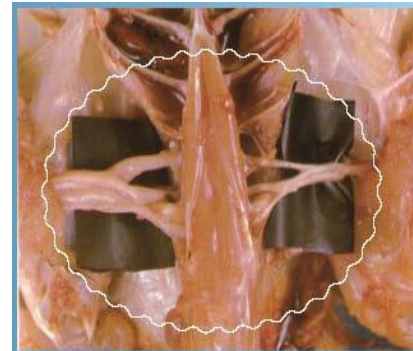
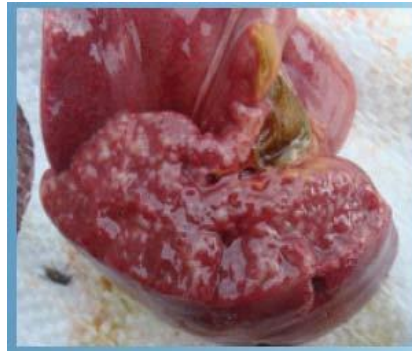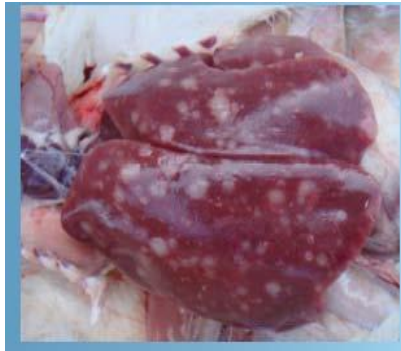Diagnosis and Misdiagnosis of MD



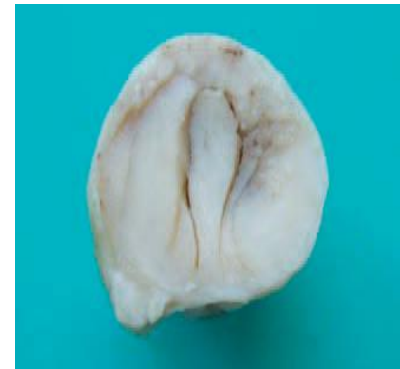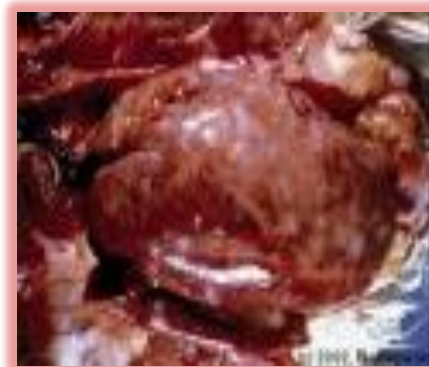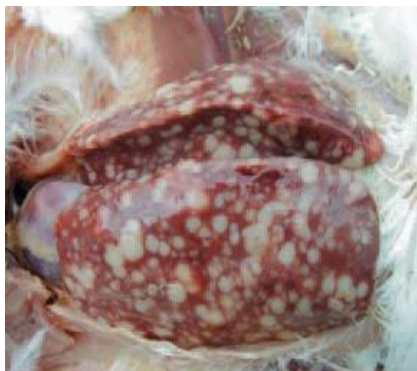- **Diagnosis:** History, clinical signs, combined with post-mortem findings, will confirm the diagnosis in most cases, and, most importantly, rule-out other diseases.
- Marek's condition can be confused with **lymphoid leukosis**. The two diseases are differentiated by: (1) the age at which birds are affected, (2) the presence and focus of lesions, (3) the presence and absence of paralysis and the category of neoplastic lymphoid cell affected.



MD and LL postmortem lesions



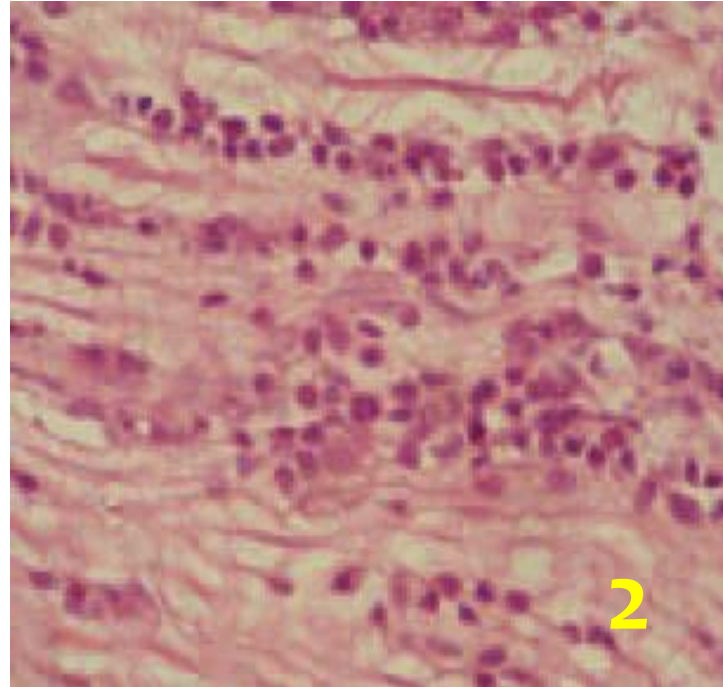
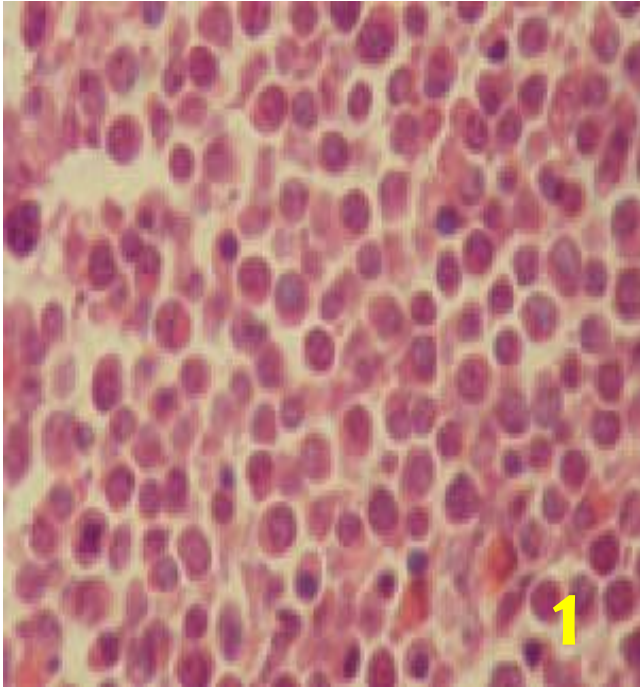
MD



LL

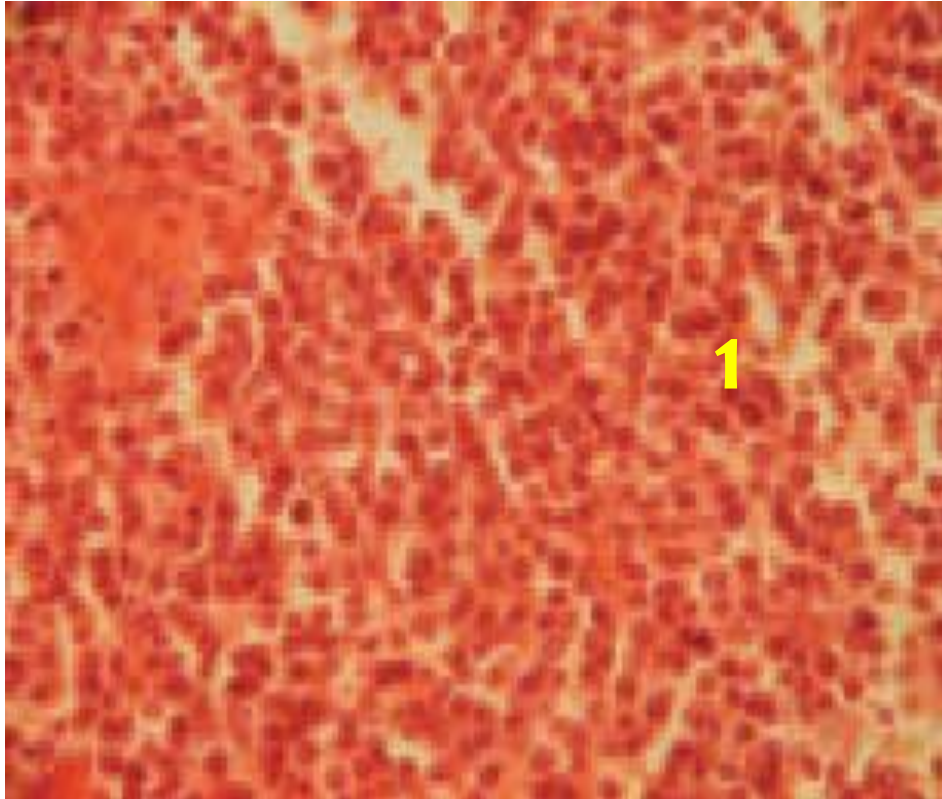


Histopathology of MD





Histopathology of LL





How to Differentiate MD from LL



- Lymphoid leucosis also causes tumors in organs, but does not cause paralysis, i.e. there are no nervous signs and lesions.
- Lymphoid leucosis is usually seen in birds over 20 weeks of age, whereas Marek's disease is commonly seen in younger chickens (less than 16 weeks of age).
- Most deaths from Marek's disease occur between 8 and 20 weeks of age, although in some cases the disease may be seen in birds as young as 3-4 weeks of age or as old as one year of age.
- Marek's disease commonly affects the T-lymphocytes whereas lymphoid leucosis commonly affects B lymphocytes.



Accurate diagnosis of MD

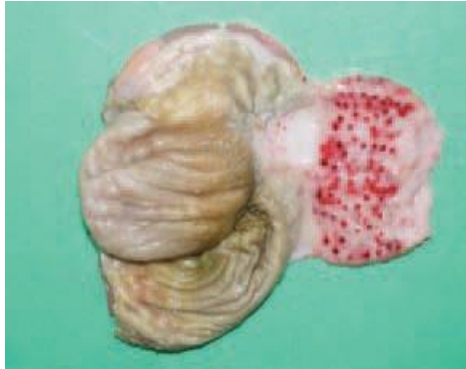

Must consider the following:

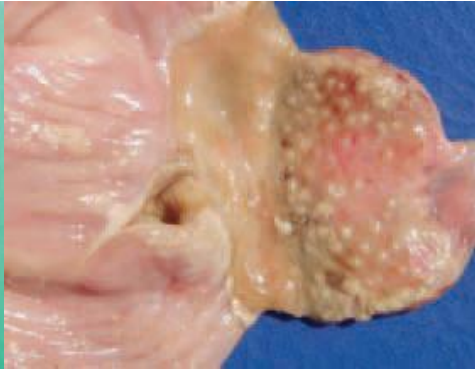
1. **History:**
 - (i) Age of birds affected (<16 wks or more?)
 - (ii) Incidence (>5% or less?)
 - (iii) Morbidity and mortality rates (high or low?)
2. **Clinical symptoms:** Leg and wing paralysis? Eye lesions?
3. **PM lesions-** Involvement of peripheral nerves?, involvement of bursa of Fabricius?
4. Simultaneous lack of alterations in the bursa of Fabricius.
5. **Histopathology:**
 - (i) type and uniformity of lymphocyte cell infiltration.
6. **Virus isolation and serology**



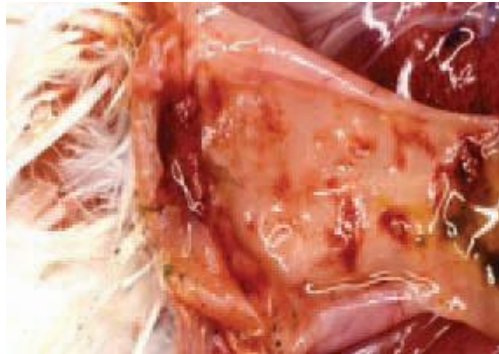New Castle Disease



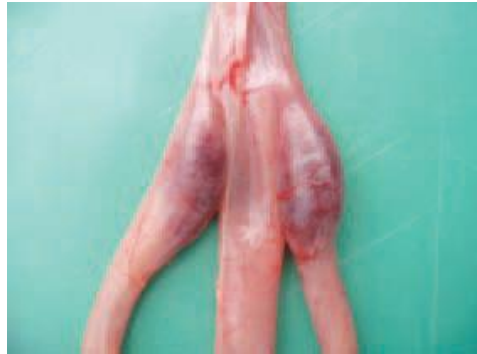1



2



3



4



Differential diagnosis of NCD



- Fowl cholera
- Avian influenza
- Laryngotracheitis
- Fowl pox (diphtheritic form)
- Psittacosis (chlamydiosis) (psittacine birds)
- Mycoplasmosis
- Infectious bronchitis
- Pacheco's parrot disease (psittacine birds)
- Fusaritoxicoses



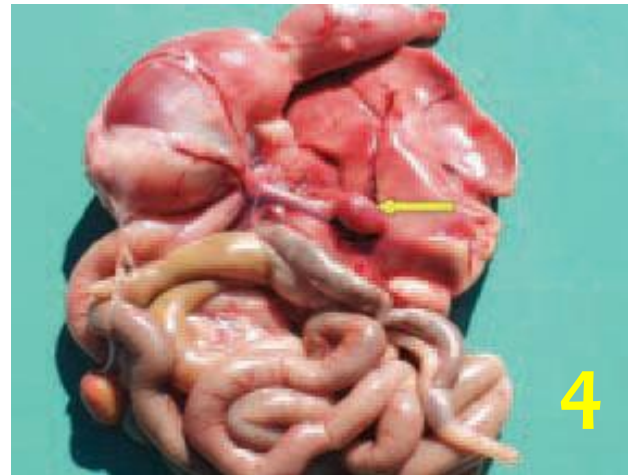
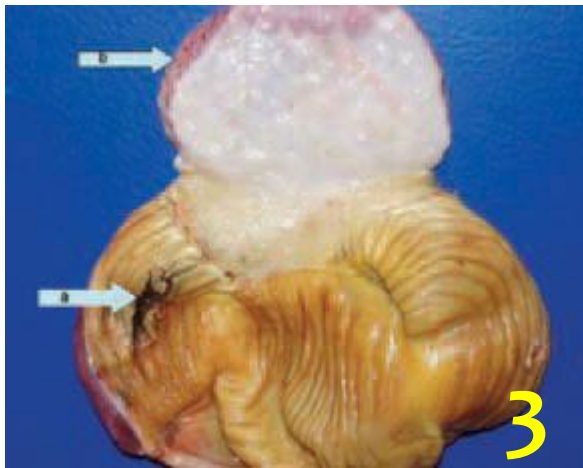
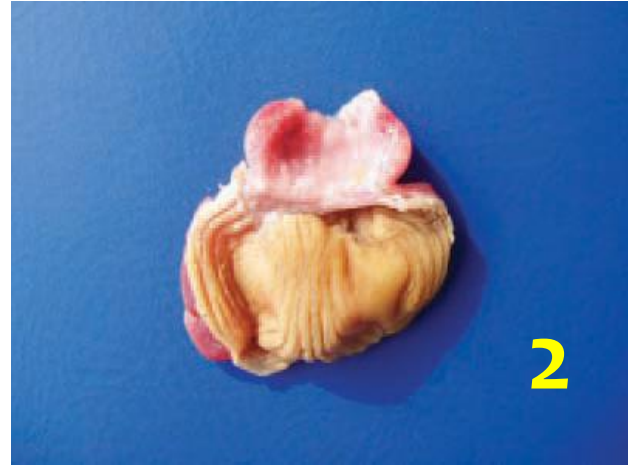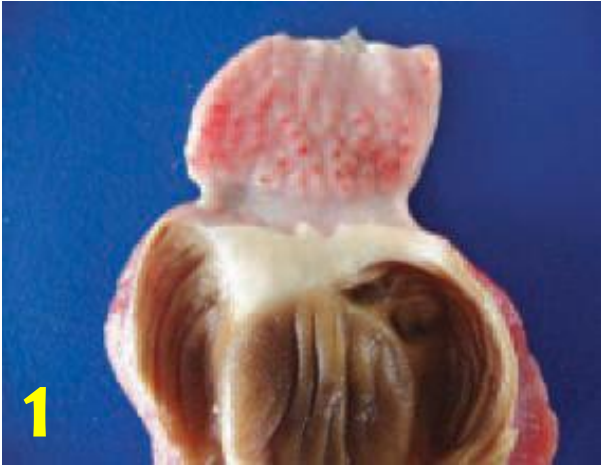Diagnosis of NCD



- **Tentative:**
 - History
 - Clinical signs- respiratory and nervous signs
 - PM lesions- not specific or pathognomonic
- **Confirmatory:**
 - Lab isolation and identification of the causative virus
 - Serology- HI and ELISA tests

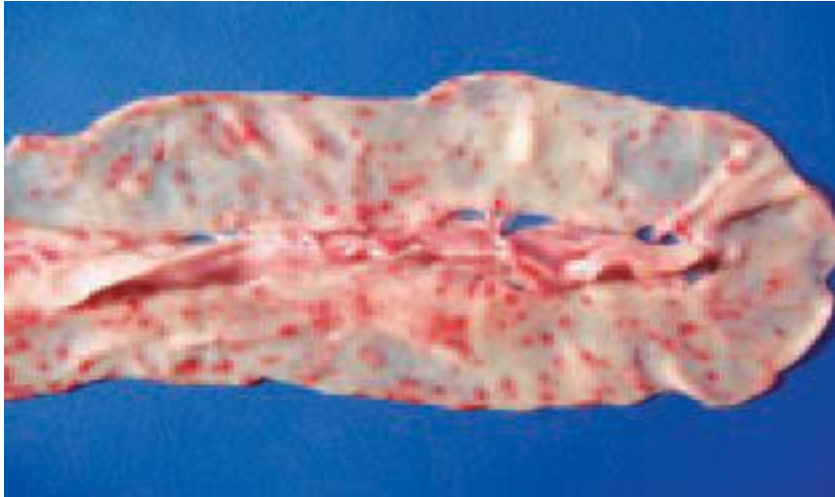


Fusaritoxicoses



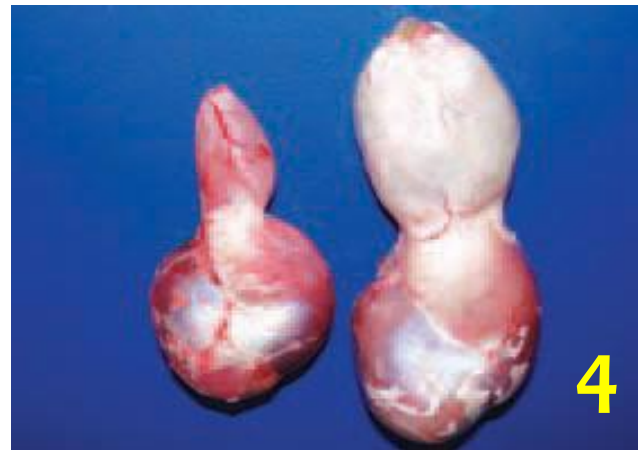
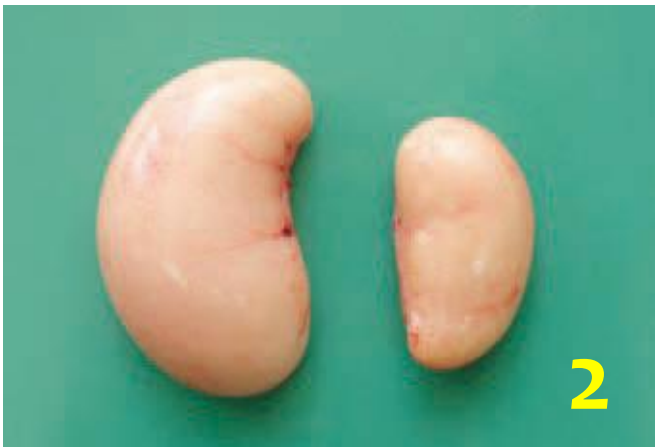
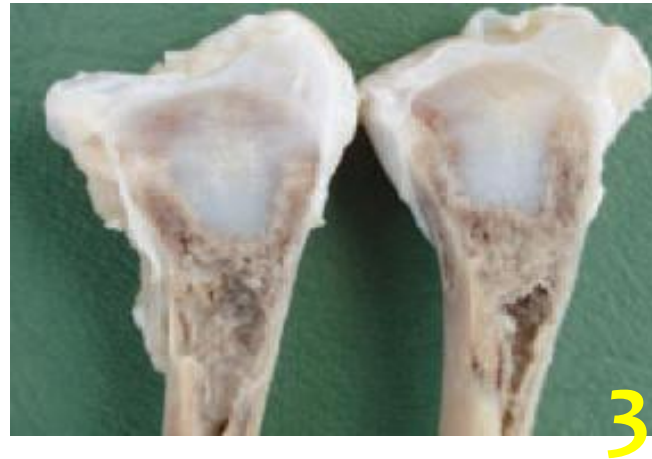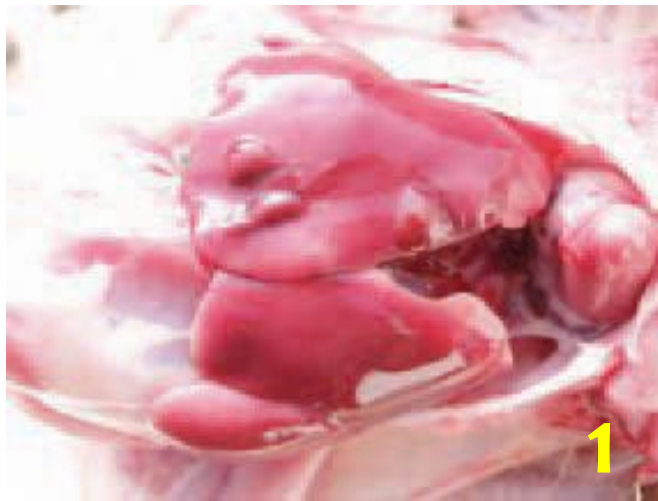Fusaritoxicoses





Other PM Lesions in Fusaritoxicoses





Diagnosis of fusaritoxicoses



- The *Fusarium* genus produces numerous mycotoxins, out of which, the most important for poultry pathology are trichothecenes, fumosinins, moniliformin, fusaro-chromanone and zearalenone.
- The *Fusarium* toxins possess a pronounced caustic effect, resulting in necroses and crusts of the buccal mucosa.
- Diagnosis entails the screening of cereals and forages for the presence of some mycotoxins (aflatoxin, T-2 toxin, zearalenone) via ELISA.



THANK YOU!

